

Sutureless Amniotic Membrane Transplantation for Ocular Surface Disorders: A Comparison of ProKera to AmbioDisk

Christina Giannikas MD; Carolyn Y. Shih MD; Anne Steiner MD; Ira J. Udell MD
Department of Ophthalmology, Hofstra North Shore-LIJ School of Medicine, Great Neck, NY

Purpose

- To evaluate and compare the indications for and outcomes of ProKera and AmbioDisk, two types of sutureless amniotic membrane devices, in the management of ocular surface disorders.

Methods

- Retrospective chart review of all patients who had ProKera (Bio-Tissue, Inc.) or AmbioDisk (IOP Ophthalmics, Inc.) application with bandage contact lens (BCL) for ocular surface disorders between August 2010 and November 2013 at a tertiary medical center's cornea practice. The parameters evaluated included age, sex, indication for device placement, effect of amniotic membrane on ocular surface healing, and tolerance. Complete success was defined as complete healing of the ocular surface without further intervention, partial success was defined as partial healing of the ocular surface requiring further intervention (BCL, tarsorrhaphy, conjunctival flap), and failure was defined as lack of documented improvement with transplant or premature discontinuation of transplant prior to demonstrable improvement. Any complications were noted. Student's t-test was used to determine the presence of statistical differences between the ProKera and AmbioDisk groups.

Results

- 22 eyes of 20 patients with a mean age of 75.5 years (Range 25-93 years) were evaluated. 73% were male. Indications for placement of sutureless amniotic membrane were nonhealing infectious corneal ulcer (ProKera 21%, AmbioDisk 13%), neurotrophic keratopathy (ProKera 43%, AmbioDisk 25%), nonhealing epithelial defect over previous corneal transplant (ProKera 14%, AmbioDisk 63%), and other (ProKera 21%, AmbioDisk 0%). There was no statistical difference between the two groups in terms of treatment indication (p=0.5). Overall success (complete and partial) was seen in 68% of eyes (ProKera 64%, AmbioDisk 75%). Complete success was seen in 45% of eyes (ProKera 43%, AmbioDisk 50%), and partial success was seen in 23% of eyes (ProKera 21%, AmbioDisk 25%). There was no statistical difference between the 2 groups (p=0.7). Of the patients who went on to require further intervention, 14% were treated with BCL (ProKera 7%, AmbioDisk 25%), 23% with tarsorrhaphy (ProKera 29%, AmbioDisk 13%), and 18% with conjunctival flap (ProKera 29%, AmbioDisk 0%). Two ProKera devices were placed with concomitant suture tarsorrhaphy, Patient intolerance was observed in the ProKera group in 7/14 eyes (50%). 1 patient with neurotrophic keratitis developed recrudescence of a hypopyon 2 days after placement of AmbioDisk.

Sutureless Amniotic Membranes

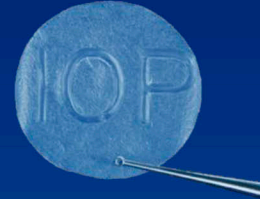Image 1:

ProKera (Bio-Tissue, Inc.) is a piece of amniotic membrane tissue in between two flexible rings.



Image 2:

AmbioDisk (IOP Ophthalmics, Inc.) is a disk-shaped overlay amniotic membrane tissue.



Clinical Cases

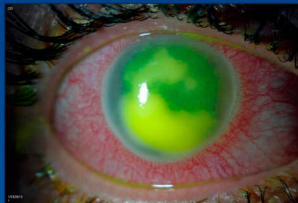


Image 3:

- 60 year old male with neurotrophic ulcer and nonhealing epithelial defect before (Image 3) and after (Image 4) treatment with ProKera.

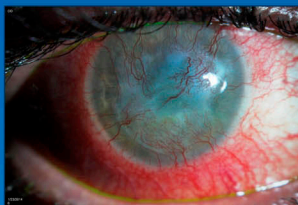

Image 4:

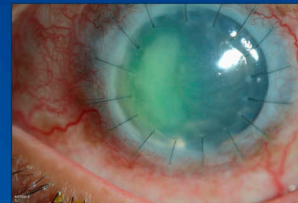


Image 5:

- 49 year old male with persistent epithelial defect in failed penetrating keratoplasty (PK) before (Image 5) and after (Image 6) treatment with AmbioDisk and BCL.

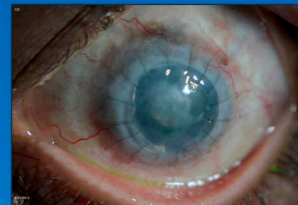

Image 6:

ProKera vs. AmbioDisk

Complete Success	45%
ProKera	43%
AmbioDisk	50%
Partial Success	23%
ProKera	21%
AmbioDisk	25%
Further Intervention Needed	32%
ProKera	36%
AmbioDisk	25%

Figure 1:

Outcome comparison between ProKera-treated and AmbioDisk-treated eyes: both modalities performed similarly across various treatment indications.

Conclusion

- Amniotic membrane device application. Amniotic membrane may promote epithelialization and reduce inflammation. ProKera and AmbioDisk are both successful in promoting healing in a variety of ocular surface disorders. Both modalities had similar success rates and there was no statistically significant difference in their performance across multiple treatment indications. ProKera had the limitation of patient intolerance in half of our cases. The incidence of deleterious side effects was minimal with both modalities. Although one patient with neurotrophic keratitis developed hypopyon 2 days after AmbioDisk placement, it is unclear whether this event was a true complication of AmbioDisk or a recurrence of inflammation related to the underlying disease. Further investigation of these two modalities in various clinical settings is needed to further evaluate their comparative efficacy.

References

- Suri K, Kosker M, Raber IM, Hammersmith KM, Nagra PK, Ayres BD, Halfpenny CP, Rapuano CJ. Sutureless amniotic membrane ProKera for ocular surface disorders: short-term results. Eye Contact Lens. 2013;39(5):341-7.
- Pachigolla G1, Prasher P, Di Pascuale MA, McCulley JP, McHenry JG, Mootha VV. Evaluation of the role of ProKera in the management of ocular surface and orbital disorders. Eye Contact Lens. 2009;35(4):172-5.
- Liang X1, Liu Z, Lin Y, Li N, Huang M, Wang Z. A modified symblepharon ring for sutureless amniotic membrane patch to treat acute ocular surface burns. J Burn Care Res. 2012;33(2):32-8.
- Kheirkhah A1, Johnson DA, Paranjpe DR, Raju VK, Casas V, Tseng SC. Temporary sutureless amniotic membrane patch for acute alkaline burns. Arch Ophthalmol. 2008;126(8):1059-66.
- Sheha H1, Liang L, Li J, Tseng SC. Sutureless amniotic membrane transplantation for severe bacterial keratitis. Cornea. 2009 Dec;28(10):1118-23.
- Park CY1, Kohanim S, Zhu L, Gehlbach PL, Chuck RS. Immunosuppressive property of dried human amniotic membrane. Ophthalmic Res. 2009;41(2):112-3.